

RETINAL DIALYSIS AND ASSOCIATED RHEGMATOGENOUS RETINAL DETACHMENT IN PATIENTS WITH NEUROFIBROMATOSIS TYPE 1: A CASE SERIES

Ronak M. Shah, BS,* Robin A. Vora, MD,† Amar P. Patel, MD†

Purpose: Although ophthalmic manifestations of neurofibromatosis Type 1 (NF1), including iris Lisch nodules and optic gliomas, have been well described, retinal involvement in these patients has yet to be established. Characterizing the relationship between NF1 and the retina is necessary to optimize outcomes for these patients.

Methods: Independent chart review of NF1 patients was conducted.

Results: Chart review yielded four patients, with a history of NF1, with subsequent retinal dialysis and rhegmatogenous retinal detachment. These four patients presented to our institution with a rhegmatogenous retinal detachment secondary to a retinal dialysis with no history of trauma. These patients also demonstrated hyperreflective choroidal abnormalities on near-infrared reflectance imaging and optical coherence tomography.

Conclusion: Seeing that patients diagnosed with NF1 are susceptible to various ocular manifestations and pathological abnormalities, routine ophthalmic examinations are essential in maintaining their ocular health and minimizing morbidity.

RETINAL CASES & BRIEF REPORTS 18:620–624, 2024

From the *Renaissance School of Medicine at Stony Brook University, Stony Brook, New York; and †Kaiser Permanente Northern California, Oakland, California.

Neurofibromatosis Type 1 (NF1), also known as von Recklinghausen disease, is an autosomal dominant neurocutaneous disorder, with significant variability in clinical presentation. In addition to its cutaneous manifestations, including café-au-lait spots and neurofibromas, there are several ophthalmic associations. Patients with NF1 may present with optic gliomas, iris Lisch nodules, plexiform neurofibromas of the eyelid or orbit, and sphenoid dysplasia.¹ More recently, several articles have described choroidal nodules, which are seen on near-

infrared reflectance (NIR) imaging and optical coherence tomography (OCT) as multiple patchy hyperreflective lesions.² However, involvement of the retina in NF1 is much less frequently seen. We describe the largest case series of patients with NF1 with spontaneous retinal dialysis and rhegmatogenous retinal detachment (RRD).^{3–5} This case series was approved by the KPNC Institutional Review Board and adhered to the Declaration of Helsinki. Informed consent was not obtained because de-identified data were used.

Case Reports

Case 1

A 21-year-old African American woman diagnosed with NF1, with genetic testing revealing the NF1 gene variant c.370_386del (p.Cys124Alafs×4), presented with a 6-month history of decreased vision in her right eye. Her systemic manifestations of NF1 included congenital pseudoarthrosis of her left tibia and café-au-lait spots. She denied having any trauma. Visual acuity with glasses

The following authors have no conflicts of interest or financial disclosures: R.M. Shah, R.A. Vora, A.P. Patel.

Reprint requests: Amar P. Patel, MD, Kaiser Permanente Northern California, 275 W. MacArthur Boulevard, Oakland, CA 94611; e-mail: amar.p.patel@kp.org

at presentation was 20/200 in the right eye and 20/25 in the left eye. Ophthalmic examination of both eyes revealed iris Lisch nodules. Furthermore, examination of the right eye revealed a retinal dialysis clockwise from 10 to 2:30 o'clock with an associated RRD clockwise from 9 to 5 o'clock involving the macula. There were signs of chronicity, which included pigment demarcation lines at the borders of subretinal fluid, subretinal pigmentation, and yellow deposits (Figure 1A). Optical coherence tomography showed shallow subretinal fluid in the macula in addition to the typical hyperreflective choroidal nodules seen in NF1, which are most evident on NIR (Figure 1B). Specifically, 13 choroidal nodules can be seen ranging in size from one-fourth to one disk diameter. She subsequently underwent scleral buckling (42 encircling band) with cryopexy and gas injection of the right eye. Best-corrected visual acuity at her 4-year follow-up was 20/100 in the right eye (Figure 1, C and D).

Case 2

A 20-year-old white woman with NF1, with positive genetic testing done at an outside hospital, presented with an 8-month history of progressive blurry vision in the left eye, with no recent history of any trauma. She also had a history of an optic glioma in her right eye, café-au-lait spots, and pseudoarthrosis in her right tibia status post below knee amputation. Visual acuity without glasses was 20/20 in the right eye and 20/400 in

the left eye. Ophthalmic examination of both eyes showed iris Lisch nodules. In addition, the left eye showed 2+ pigmented cells in the anterior chamber and 1+ pigmented cells in the vitreous. There was a retinal dialysis from 10 to 11 o'clock with almost a total RRD sparing the inferior periphery. Optical coherence tomography showed subretinal fluid in the macula with edema (Figure 2A). She underwent scleral buckling (4,050 encircling band) with cryopexy and gas injection of the left eye. Best-corrected visual acuity ultimately improved to 20/150 in the left eye at her 5-year follow-up. Near-infrared reflectance-optical coherence tomography at follow-up showed four choroidal nodules, ranging in size from one-half to one disk diameter, which were not apparent on the preoperative NIR-OCT with a detached retina. This is likely because of the amount of subretinal fluid, secondary to the retinal detachment, that impeded imaging of the choroid (Figure 2B).

Case 3

A 21-year-old man with a history of NF1, with positive genetic testing done at an outside hospital, presented for a routine eye examination. His systemic manifestations of NF1 included pilocytic astrocytoma and café-au-lait spots. The patient denied having any trauma. Visual acuity without glasses was 20/30 in the right eye and 20/20 in the left eye. Ophthalmic examination of both eyes displayed iris Lisch nodules. Ophthalmic examination of the right eye showed a retinal dialysis 3 to 5 o'clock with an associated RRD

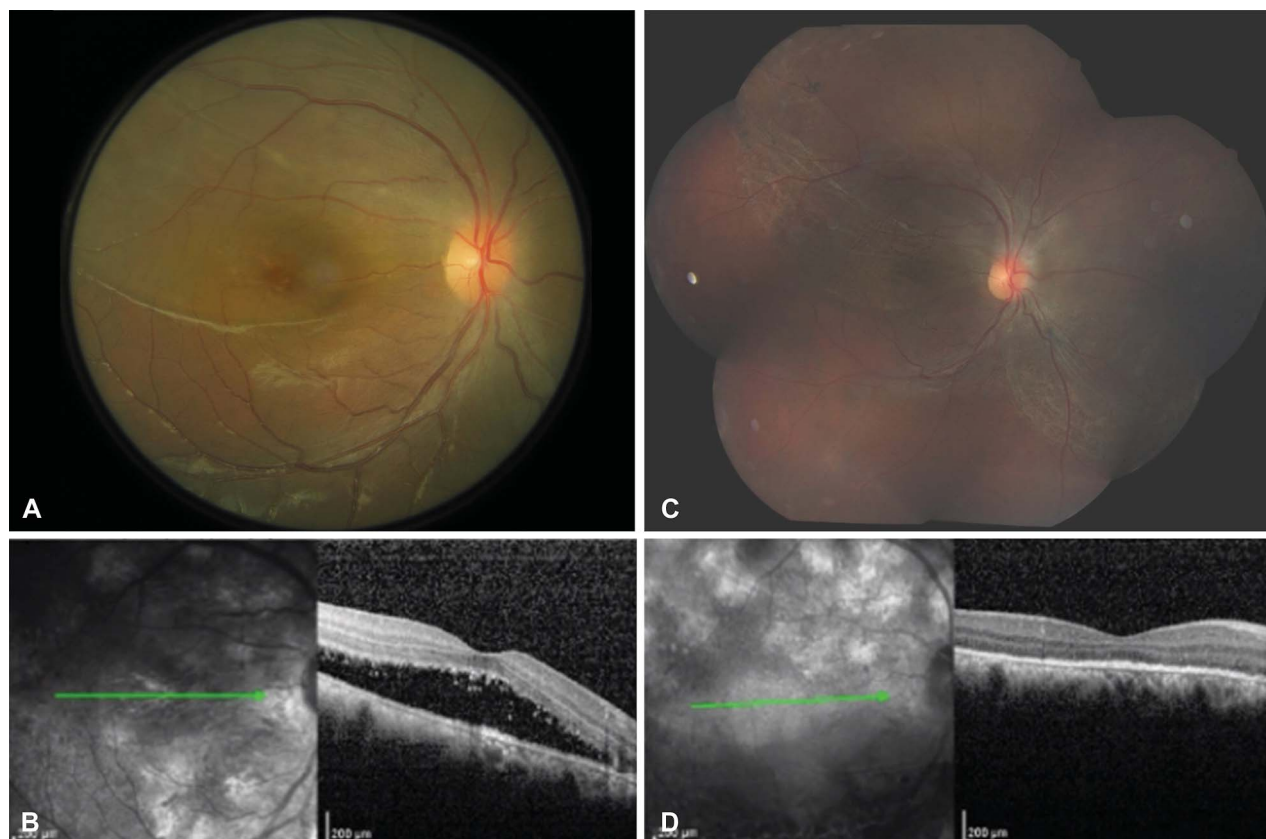


Fig. 1. A. Fundus photography of the right eye of Patient 1 demonstrating a rhegmatogenous retinal detachment involving the macula. B. Near-infrared reflectance imaging and optical coherence tomography of the right eye of the patient displaying shallow subretinal fluid and characteristic hyperreflective choroidal nodules. C. Fundus photography of the right eye of the patient post scleral buckling showing an attached retina with residual pigment demarcation lines and subretinal pigment. D. Near-infrared reflectance imaging and optical coherence tomography of the right eye of the patient post scleral buckling showing hyperreflective choroidal nodules. The retina is attached with disruption of ellipsoid zone.

Downloaded from http://journals.lww.com/retinalcases by g3NG442gFk/qRmORIVVH5IAEEnS8vbX1onRtdSEmuyg KZFSyB4soTlUJDH/EHLK7mMg7YJf1f6mknUR/199z7Gh+TR15P0odX8ZL0gV7L+C3HC1bVhPQEEo1QJkG on 09/24/2024

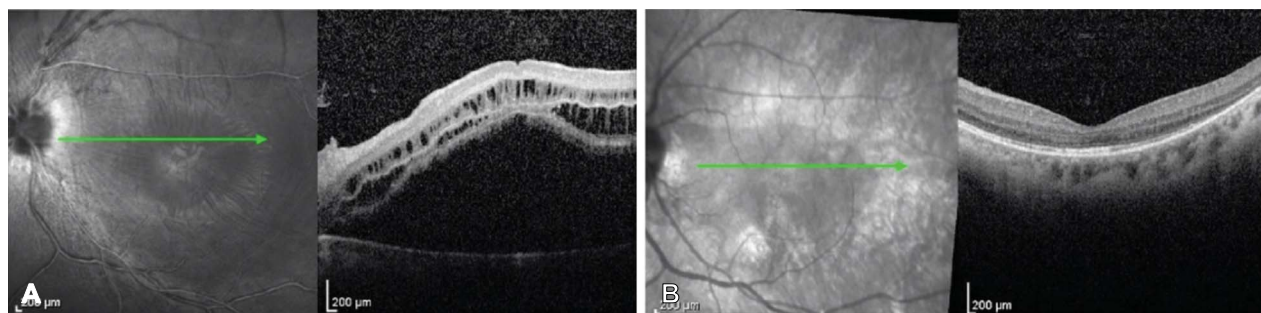


Fig. 2. A. Near-infrared reflectance imaging and optical coherence tomography of the left eye of Patient 2 displaying subretinal fluid and edema in the macula. B. Near-infrared reflectance imaging and optical coherence tomography of the left eye of the patient at follow-up after scleral buckling demonstrating an attached retina with choroidal nodules.

from 2 to 7 o'clock extending to the optic nerve and inferior arcade. Examination of the left also showed a retinal dialysis from 4 to 6 o'clock without an RRD. Near-infrared reflectance imaging and optical coherence tomography of the right eye showed an attached macula with subretinal fluid up to the inferior arcade in addition to five hyperreflective choroidal nodules, ranging in size from one-fourth to one disk diameter (Figure 3A). A total of four choroidal nodules in the left eye, ranging in size from one-fourth to one disk diameter, were visualized through NIR-OCT as well (Figure 3B). The patient underwent scleral buckling (4,050 segmental buckle) with cryopexy, external drainage, and gas injection in the right eye and barrier laser retinopexy in the left eye. At 3-month follow-up his retina was attached with best-corrected visual acuity of 20/20 in both eyes.

Case 4

A 14-year-old Hispanic boy with NF1, with genetic testing revealing the NF1 gene mutation at splice donor site of exon 10b c.1527+1G > T, presented because of a failed school eye examination. He also had a history of optic nerve gliomas on both eyes, cutaneous neurofibromas, and café-au-lait spots. He denied having any trauma. Visual acuity without glasses as 20/25 in the right eye and 20/400 in the left eye. Examination of both eyes displayed iris Lisch nodules, with the left eye revealing a retinal detachment from 2 to 10 o'clock involving the macula and a retinal dialysis from 3 to 5:30 o'clock. Scleral buckling (240 encircling band) with cryopexy, external drainage, and gas injection was performed. Best-corrected visual acuity at his 5-year follow-up was 20/200 in the left eye. Postoperative NIR-OCT showed nine hyperreflective choroidal nodules, ranging in size from three-fourth to one disk diameter (Figure 4).

Discussion

Although general ophthalmic presentations of NF1 have been well established, including plexiform neurofibromas and sphenoid dysplasia, retinal dialysis is not largely described as an associated condition. Shrestha et al,³ Clemente-Tomas et al,⁴ and Oudbib et al⁶ each reported one case of a 36-year-old, 13-year-old, and 15-year-old patient, respectively, with a history of NF1 presenting with RRD secondary to retinal dialysis without any history of trauma. This relationship is also explored by Destro et al⁵ who reported two patients, aged 15 and 17 years, respectively, with a history of NF1 and RRD secondary to retinal dialysis. Our study is the largest case series of patients that describes the association between retinal dialysis and NF1 and adds to the current literature by characterizing the presence of hyperreflective choroidal abnormalities in these patients as well. In our study, all four cases presented with chronic retinal detachments or retinal detachments that were detected incidentally.

It is hypothesized that patients with NF1 may be more susceptible to retinal dialysis due to altered fibroblasts. The vitreous base is a structure that surrounds the ora serrata, extending 2 mm anteriorly to 3 mm posteriorly. Housed within the vitreous base is a high density of collagen fibrils, and thus

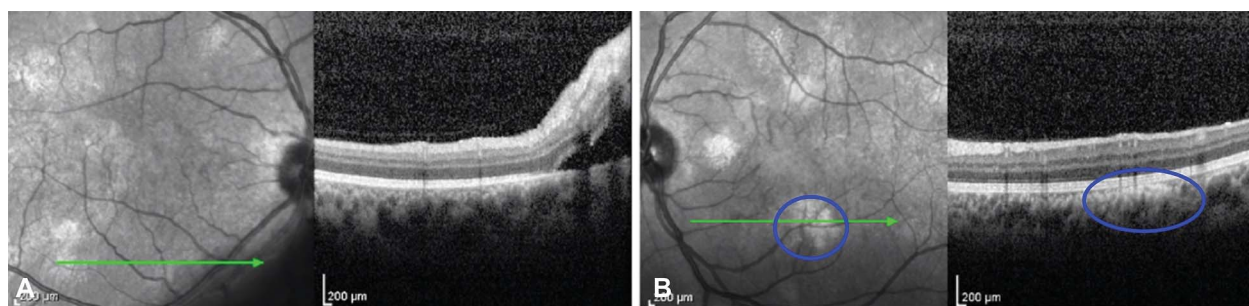


Fig. 3. A. Near-infrared reflectance imaging and optical coherence tomography of the right eye of Patient 3 showing subretinal fluid inferonasally along with hyperreflective choroidal nodules. B. Near-infrared reflectance imaging and optical coherence tomography of the left eye of the patient demonstrating hyperreflective choroidal nodules (blue circle on NIR that corresponds to blue circle on OCT).

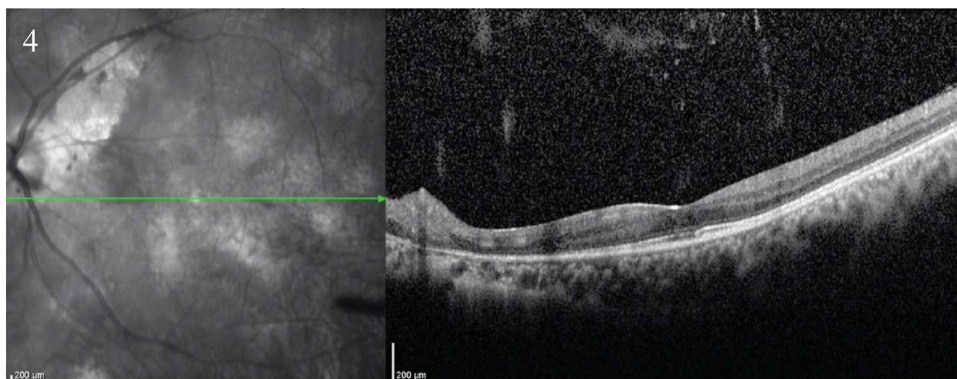


Fig. 4. Near-infrared reflectance imaging and optical coherence tomography of the left eye of patient four at follow-up after scleral buckling demonstrating hyperreflective choroidal nodules. The retina is attached with atrophy nasally.

fibroblasts, oriented 90° to the peripheral retina. Neurofibromatosis Type 1 has been shown to impede the growth of fibroblasts and alter their morphology.⁷ Furthermore, NF1 fibroblasts appear to have a diminished response to epidermal growth factor, a protein that plays a critical role in collagen production and cell renewal through fibroblast interaction with keratinocytes.⁷ Through NF1-associated fibroblast changes in the vitreous base, stability between the vitreous base and pars plana anteriorly and peripheral retina posteriorly may be compromised. This may ultimately result in subsequent dialysis and RRD.

This case series also confirmed the presence of choroidal nodules seen most easily on NIR imaging. Although iris Lisch nodules are considered the most prominent ocular manifestation of NF1, choroidal nodules have shown a significant association with this condition as well. Near-infrared reflectance imaging suggests that choroidal nodules may in fact be present more often than Lisch nodules in NF1, with choroidal abnormalities in more than 70% of patients.⁸ In addition, NF1 patients appear to be more susceptible to retinal vascular abnormalities as a result of their association with choroidal nodules.² Through the use of optical coherence tomography angiography, diminished choriocapillaris blood flow in NF1 patients, possibly stemming from choroidal nodules obstructing the choriocapillaris, can be visualized.^{2,9} These retinal vascular abnormalities can ultimately lead to various retinal pathological abnormalities.⁹ Taken together, the increased presentation of choroidal nodules in NF1 and their association with retinal vascular abnormalities highlight their promise as new possible diagnostic criteria for this neurocutaneous disorder.

Current screening guidelines for patients with NF1 recommend annual fundoscopic examination in all children younger than 8 years and at least every two years thereafter.¹⁰ Various ophthalmic features of NF1 have already been well described. Although retinal

dialysis and associated RRD has not been largely explored, the urgent nature of RRD and its potential to result in significant vision loss, coupled with the already well-described ophthalmic findings of NF1, warrant adherence to current screening recommendations and patient education regarding the importance of routine eye examination.^{3,4} Considering the ophthalmic manifestations of NF1 and the susceptibility of NF1 patients to other ocular conditions, including glaucoma and optic nerve glioma, regular dilated fundus examination is necessary to minimize morbidity and optimize outcomes.

Conclusion

Our case series emphasizes the need for routine ophthalmic examination in patients diagnosed with NF1. The relationship between NF1 and RRD warrants a dilated fundus examination, irrespective of symptoms and visual acuity, to examine the peripheral retina for retinal dialysis and RRD.

Key words: neurofibromatosis, retinal detachment, retinal dialysis.

References

1. Kinori M, Hodgson N, Zeid JL. Ophthalmic manifestations in neurofibromatosis type 1. *Surv Ophthalmol* 2018;63:518–533.
2. Vagge A, Corazza P, Ferro Desideri L, et al. Ocular biometric parameters changes and choroidal vascular abnormalities in patients with neurofibromatosis type 1 evaluated by OCT-A. *PLoS One* 2021;16:e0251098.
3. Shrestha RM, Bhatt S, Shrestha P, et al. Rhegmatogenous retinal detachment with spontaneous dialysis of the Ora serrata in neurofibromatosis type 1: a case report. *J Nepal Med Assoc* 2022;60:555–558.
4. Clemente-Tomas R, Ruiz-Del Río N, Gargallo-Benedicto A, et al. Retinal detachment with spontaneous dialysis of the ora serrata in a 13-year-old child with neurofibromatosis type 1: a case report. *Indian J Ophthalmol* 2020;68:1473–1475.
5. Destro M, D'Amico DJ, Gragoudas ES, et al. Retinal manifestations of neurofibromatosis. Diagnosis and management. *Arch Ophthalmol* 1991;109:662–666.

6. Oudbib M, Ibrahim F, Hajji Z, et al. Neurofibromatosis type 1 revealed by A retinal detachment caused by A spontaneous desinsertion at the oraserrata. *J Dental Med Sci* 2018;17:82–84.
7. Zerkowitz M, Stambouly J. Short communication: neurofibromatosis fibroblasts: slow growth and abnormal morphology. *Pediatr Res* 1981;15:290–293.
8. Moramarco A, Giustini S, Nofroni I, et al. Near-infrared imaging: an in vivo, non-invasive diagnostic tool in neurofibromatosis type 1. *Graefe's Archive Clin Exp Ophthalmol* 2018;256:307–311.
9. Koçer AM, Atesoglu Hİ, Yılmaz A, Çıtırık M. Quantitative OCT angiography of the retinal and choroidal vascular circulation in pediatric patients with neurofibromatosis type 1. *J Am Assoc Pediatr Ophthalmol Strabismus* 2022;26:189.e1–189.e6.
10. Cassina M, Frizziero L, Opocher E, et al. Optic pathway glioma in type 1 neurofibromatosis: review of its pathogenesis, diagnostic assessment, and treatment recommendations. *Cancers (Basel)* 2019;11:1790.