

Tonic Seizures in a Patient With Lennox–Gastaut Syndrome Manifest as “Icicles” Rather Than “Flames” on Quantitative EEG Analysis

Eva Catenaccio, Mariko L. Bennett, Shavonne L. Massey, Nicholas S. Abend, and Christina Bergqvist

Division of Pediatric Neurology, Department of Pediatrics, Children’s Hospital of Philadelphia, Philadelphia, Pennsylvania, U.S.A.

Summary: Quantitative analysis of continuous electroencephalography (QEEG) is increasingly being used to augment seizure detection in critically ill patients. Typically, seizures manifest on QEEG as abrupt increases in power and frequency, a visual pattern often called “flames.” Here, we present a case of a 16-year-old patient with intractable Lennox–Gastaut syndrome secondary to a pathogenic variant in the *SCN2A* gene who had tonic seizures that manifest as abrupt

decreases in power on QEEG, a visual pattern we term “icicles.” Recognition of QEEG patterns representative of different seizure types is important as QEEG use becomes more widespread including in pediatric populations.

Key Words: Quantitative EEG.

(J Clin Neurophysiol 2023;40: e6–e9)

Continuous electroencephalography (CEEG) is widely used as a neuromonitoring tool in critically ill patients with or at risk for brain injury in conditions such as status epilepticus, hypoxic–ischemic injury after cardiac arrest, and traumatic brain injury.¹ CEEG can be used to identify electrographic-only or subtle clinical seizures and to assess response to treatment of seizures. Traditionally, CEEG is reviewed intermittently by neurophysiologists or EEG technologists, which is time-intensive and requires extensive specialized training.

Quantitative analysis of raw EEG data (QEEG) can enhance the efficiency of EEG interpretation and allow for real-time bedside interpretation by nonneurophysiologists. Quantitative electroencephalography relies on the application of mathematical transformations of raw EEG data to summarize features of cerebral activity, including the power or degree of rhythmicity across different frequencies. Quantitative electroencephalography trends are displayed on compressed time scales using color density spectral arrays. As with conventional EEG, specific QEEG patterns are recognizable. For example, seizures typically manifest as abrupt increases in power and frequency compared with baseline activity. The visual signature of a seizure on QEEG is often referred to as a “flame” (Fig. 1).²

There is evidence that QEEG can augment conventional CEEG interpretation for the detection of seizures in children and adults.^{3–5} However, recognizing atypical QEEG patterns specific to certain

seizure types is necessary as QEEG gains more widespread use in children.⁶

CASE PRESENTATION

A 16-year-old patient with intractable Lennox–Gastaut syndrome secondary to a pathogenic variant in the *SCN2A* gene presented with increased frequency of tonic seizures with a respiratory infection. Continuous electroencephalography identified numerous tonic seizures (Fig. 2A), which resolved after the initiation of a midazolam infusion. Unlike the typical “flames” pattern seen with most seizure types, this patient’s QEEG demonstrated an atypical pattern of decreased power (“icicles”) compared with the baseline high-amplitude background (Fig. 2B).

DISCUSSION

This patient’s QEEG “icicle” pattern of decreased power was associated with tonic seizures, which are most often seen in pediatric patients and/or patients with Lennox–Gastaut syndrome.^{7,8} On conventional EEG, tonic seizures are often associated with an electrodecrement and emergence of generalized paroxysmal fast activity.⁹ The icicle QEEG pattern observed in this patient reflects the relative electrodecrement seen on the conventional EEG, and in theory, it could be seen with other phenomenon associated with a similar EEG pattern such as state changes, other seizure types, or artifacts. As with all QEEG interpretation, correlation with the conventional EEG is necessary. Future studies including additional patients will need to assess whether this pattern is specific for tonic seizures. Although most studies evaluating QEEG have been performed in adults, this case highlights that assessment of QEEG patterns in children may be important given differences in seizure types. In addition, as patients with Lennox–Gastaut syndrome often continue to have these seizures as adults, recognition of this QEEG pattern is relevant for adult neurology providers.

The authors declare that they have no affiliations with or involvement in any organization or entity with any financial interest in the subject matter or materials discussed in this manuscript.

All procedures performed in studies involving human participants were in accordance with the ethical standards of the institutional and/or national research committee and with the 1964 Declaration of Helsinki and its later amendments or comparable ethical standards.

E. Catenaccio has received funding from the American Academy of Pediatrics; N. S. Abend has received funding from the Wolfson Family Foundation. Address correspondence and reprint requests to Eva Catenaccio, MD, Children’s Hospital of Philadelphia, 3401 Civic Center Boulevard, Philadelphia, PA 19104, U.S.A.; e-mail: catenaccio@chop.edu.

Copyright © 2022 by the American Clinical Neurophysiology Society
ISSN: 0736-0258/22/4002-0006
DOI 10.1097/WNP.0000000000000974

Downloaded from https://pubs.ascp.org/ by guest on 06/05/2023

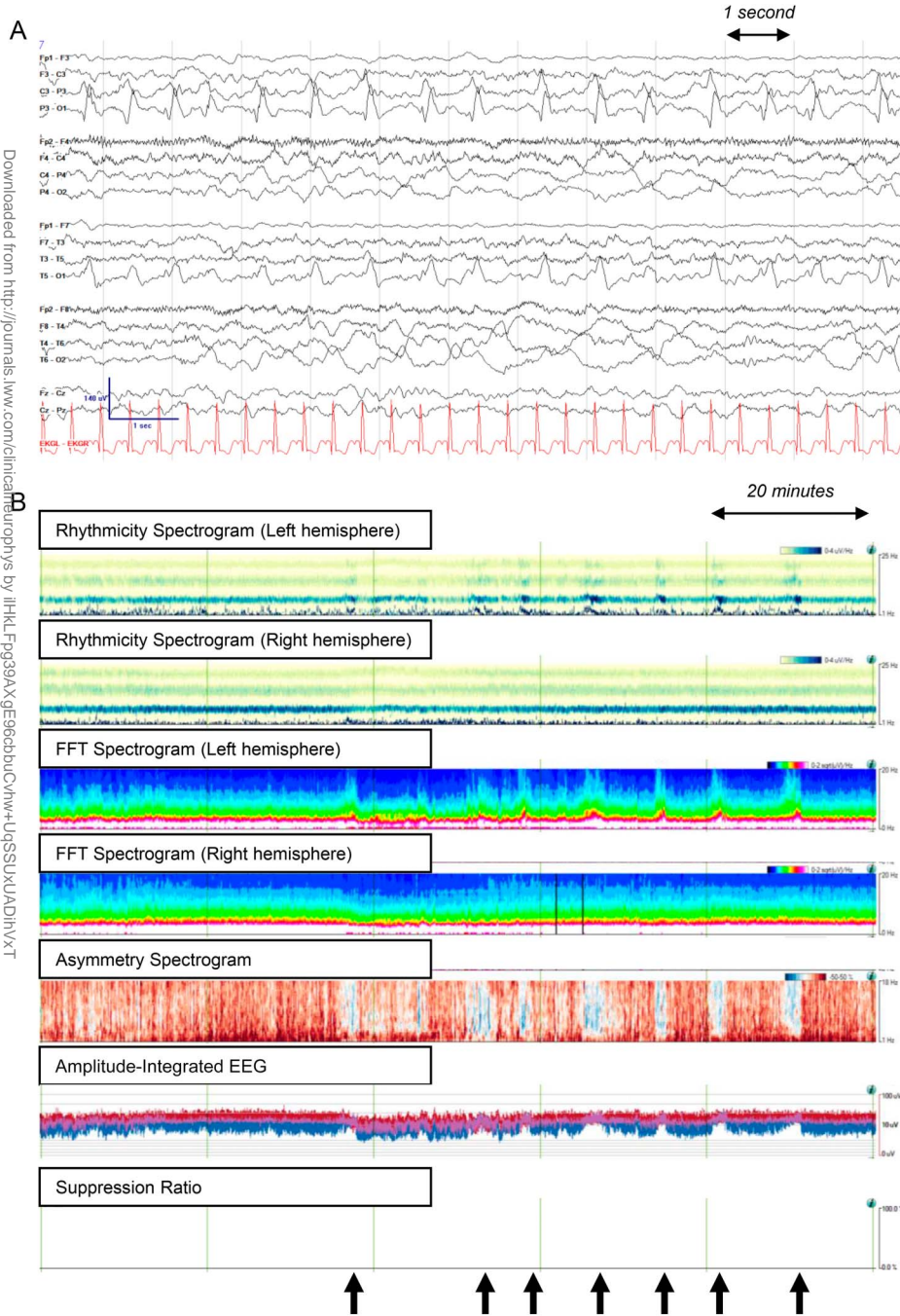


FIG. 1. **A**, CEEG of a 4-month-old patient with focal seizures arising from the left parieto-occipital region. **B**, On QEEG, seizures (black arrows) manifest as abrupt increases in rhythmicity (rhythmicity spectrogram), power (FFT spectrogram), relative left hemispheric power (asymmetry spectrogram), and peak-to-peak amplitude (amplitude-integrated EEG). There is no change in the suppression ratio. The visual pattern of a seizure on the FFT spectrogram is often referred to as a “flame.” CEEG, continuous electroencephalography; FFT, fast Fourier transform; QEEG, quantitative electroencephalography.

Downloaded from https://onlinelibrary.wiley.com/doi/10.1111/j.1469-7610.2022.02611.x by University of California, San Diego, Wiley Online Library on [06/05/2023]. See the Terms and Conditions (https://onlinelibrary.wiley.com/terms-and-conditions) on Wiley Online Library for rules of use; OA articles are governed by the applicable Creative Commons License

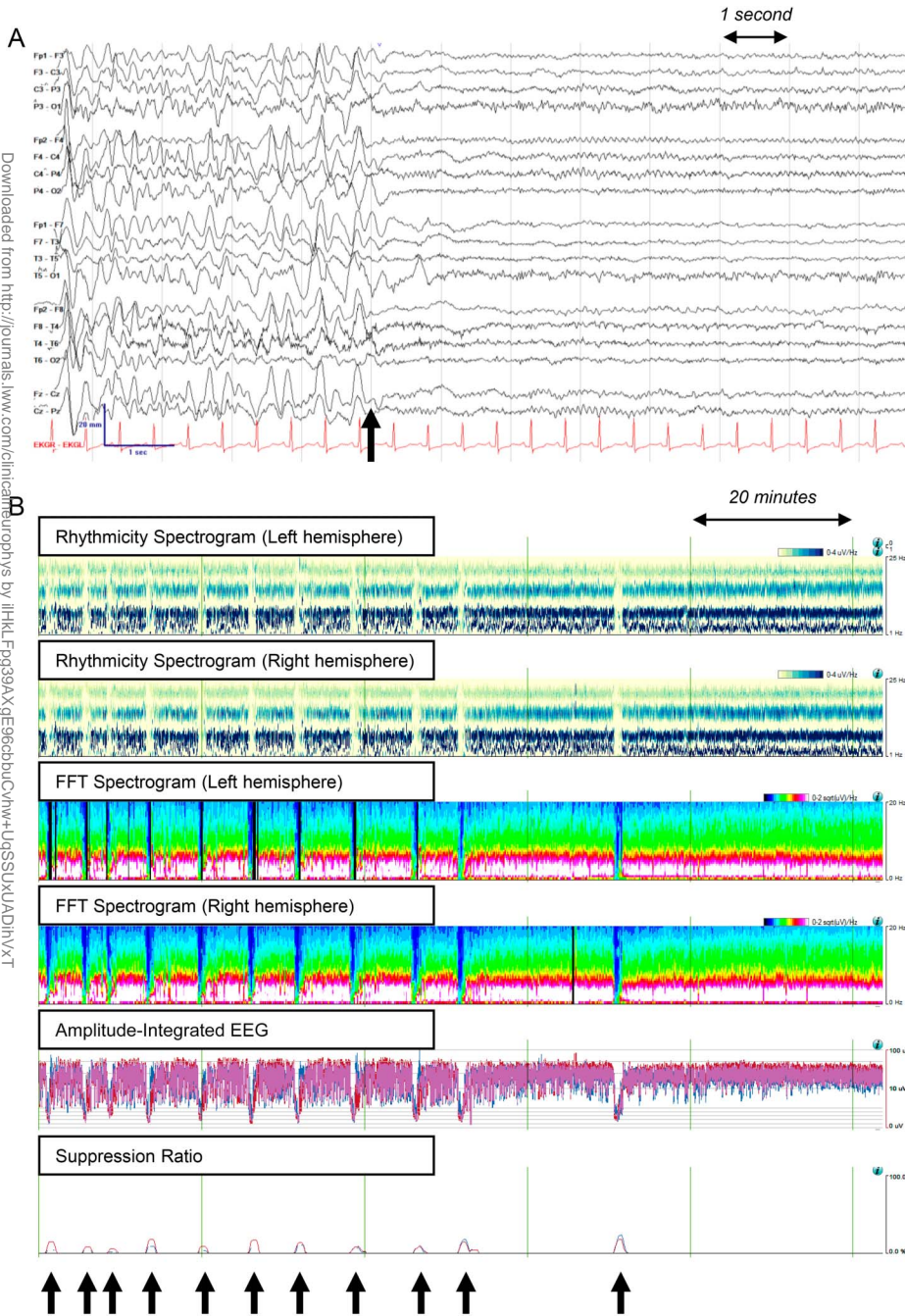


FIG. 2. A, CEEG in a 16-year-old patient with Lennox–Gastaut syndrome secondary to a pathogenic *SCN2A* variant, which demonstrated a diffusely slow background punctuated by high-amplitude rhythmic 1 to 2 Hz sharp-and-wave discharges. Seizures consist of a diffuse attenuation of background activity with the emergence of low-amplitude fast activity, associated with bilateral tonic stiffening (black arrow). B, On QEEG, seizures (black arrows) manifest as abrupt decreases in rhythmic background activity (rhythmicity spectrogram), decreases in power across all frequency bands (FFT spectrogram), and decreases in amplitude (amplitude-integrated EEG). The visual pattern of the seizure on the FFT spectrogram we refer to as an “icicle.” CEEG, continuous electroencephalography; FFT, fast Fourier transform; QEEG, quantitative electroencephalography.

REFERENCES

1. Herman ST, Abend NS, Bleck TP, et al; Critical Care Continuous EEG Task Force of the American Clinical Neurophysiology Society. Consensus statement on continuous EEG in critically ill adults and children, part I: indications. *J Clin Neurophysiol* 2015;32:87–95.
2. Ng MC, Jing J, Westover MB. *Atlas of Intensive Care Quantitative EEG*. Springer Publishing Company, 2020.
3. Swisher CB, White CR, Mace BE, et al. Diagnostic accuracy of electrographic seizure detection by neurophysiologists and non-

- neurophysiologists in the adult ICU using a panel of quantitative EEG trends. *J Clin Neurophysiol* 2015;32:324–330.
4. Haider HA, Esteller R, Hahn CD, et al; Critical Care EEG Monitoring Research Consortium. Sensitivity of quantitative EEG for seizure identification in the intensive care unit. *Neurology* 2016;87:935–944.
5. Kang JH, Sherill GC, Sinha SR, Swisher CB. A trial of real-time electrographic seizure detection by neuro-ICU nurses using a panel of quantitative EEG trends. *Neurocrit Care* 2019;31:312–320.
6. Goenka A, Boro A, Yozawitz E. Comparative sensitivity of quantitative EEG (QEEG) spectrograms for detecting seizure subtypes. *Seizure* 2018;55:70–75.

Downloaded from https://onlinelibrary.wiley.com/doi/10.1111/j.1469-7610.2023.02511.x by University of California, San Diego, Wiley Online Library on [06/05/2023]. See the Terms and Conditions (https://onlinelibrary.wiley.com/terms-and-conditions) on Wiley Online Library for rules of use; OA articles are governed by the applicable Creative Commons License

7. Fernandez-Baca Vaca G, Mayor CL, Losarcos NG, Park JT, Luders HO. Epileptic seizure semiology in different age groups. *Epileptic Disord* 2018;20:179–188.
8. Fisher RS. The new classification of seizures by the international league against epilepsy 2017. *Curr Neurol Neurosci Rep* 2017;17:48.
9. Britton JW, Frey LC, Hopp JL, et al. Electroencephalography (EEG): An Introductory Text and Atlas of Normal and Abnormal Findings in Adults, Children, and Infants. In: Louis EKS, Frey LC, eds. Chicago: American Epilepsy Society, 2016.

Downloaded from <http://journals.lww.com/clinicalneurophys> by jlhkL Fq39AXge96abbucvhw+LqSSUXUADihvX-T
lbeih+ia+4N3YK0KXALUB8SYDILLPQRINISdwwF87PpZ7O1ixg+2G6+IBgoxak\NINWKLPUdMArYQIEKKJLofObujljbvO6pl
tC65JXQ0bFdn7ZITZPUSLBNMIPHzYul5Txwpmr/ChUqoypg7hieMNU09g29IwwVM= on 06/05/2023